

Case Reports:

Cerebral Magnetic Resonance Spectroscopy at 1.5T and 3T

Marc Agzarian, BMBS (Hons), FRANZCR; Angela Walls, M.MedSc, B.App.Sc.Med Rad.

Division of Medical Imaging, Flinders Medical Centre, Bedford Park, South Australia, Australia

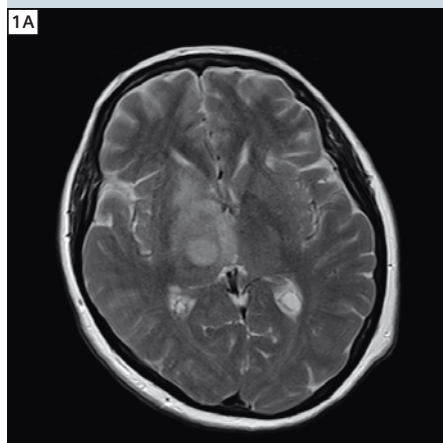
Introduction

This is a pictorial review of cerebral magnetic resonance spectroscopy (MRS) using a 1.5T MAGNETOM Aera system with software version *syngo* MR D11 and a 20-channel head and neck coil and a 3T MAGNETOM Trio system with software version *syngo* MR B15 and a 12-channel head matrix coil at Flinders Medical Centre, South Australia, Australia.

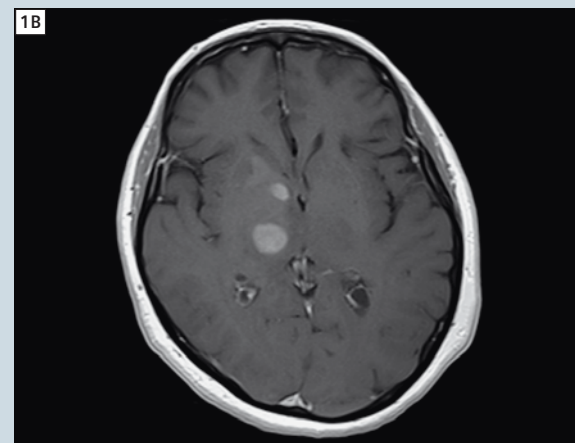
Magnetic resonance spectroscopy refers to the process of performing a chemical analysis in-vivo by the Fourier transform of the magnetic resonance signal from a voxel of tissue. Hydrogen nuclei (^1H protons) are used for clinical cerebral MRS. Proton spins in different molecules have slightly different Larmor frequencies. These differences are known as the chemical shift and are expressed in parts per million (ppm). Chemical shifts are usually referenced to the Larmor frequency of tetramethylsilane (TMS) which is given a chemical shift of zero ppm. All in-vivo molecules of interest have chemical shifts that increase their Larmor frequencies relative to TMS and are thus shown on the spectrogram to the left of zero.

Cerebral MRS can be acquired using two techniques, point resolved spectroscopy sequence (PRESS) and stimulated echo acquisition mode (STEAM). PRESS has become the most commonly used technique as it has a higher signal-to-noise ratio than STEAM. Both techniques can

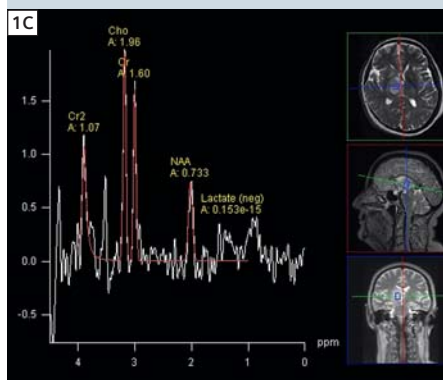
Case 1: Right thalamic glioblastoma multiforme



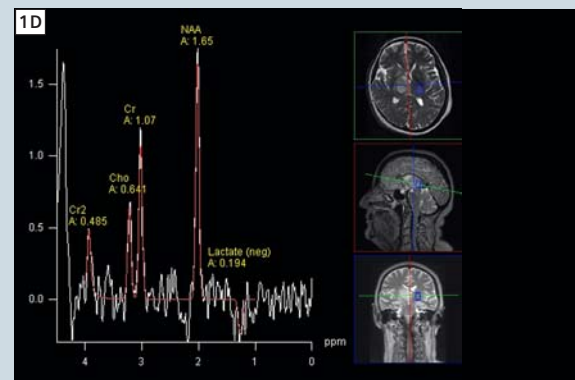
1A T2w TSE axial.



1B T1w SE post-gadolinium axial.



1C Multi-voxel PRESS MRS (TE 135 ms) within the lesion in the right thalamus.



1D Multi-voxel PRESS MRS (TE 135 ms) within normally appearing left thalamus.

be used in either single-voxel or multi-voxel acquisitions. Single-voxel acquisitions provide a better quality spectrogram from just one region of interest at a time whereas multi-voxel acquisitions provide a lesser quality spectrogram from a grid of voxels acquired simultaneously. Multi-voxel MRS can be performed using PRESS or STEAM in 2D or 3D with additional phase encoding steps. Multi-voxel MRS is also known as chemical shift imaging (CSI) or magnetic resonance spectroscopic imaging (MRSI). Regardless of the technique and acquisition used,

the essential requirement for MRS is exceptionally good magnetic field homogeneity.

Cerebral MRS is usually acquired at one or more of three different echo times, short (TE 30 – 35 ms), intermediate (TE 135 – 144 ms) and long (TE 270 – 288 ms). The short echo time is better at resolving the peaks of myoinositol, glutamine, glutamate and lipids whilst the long echo time tends to have less baseline noise. The intermediate echo time is used to confirm the presence of lactate as the lactate peak inverts.

The key normal resonant peaks in cerebral MRS are N-acetyl-aspartate (NAA) at 2 ppm, creatine (Cr) at 3 ppm and 3.9 ppm and choline (Cho) at 3.2 ppm. Whilst there is some regional variation in the brain, the NAA peak is normally the highest in the spectrum.

Tips for performing cerebral MRS

On older generation MRI scanners, achieving high quality MRS was a difficult feat. With improved magnetic field homogeneities, higher field strengths and optimised software, performing MRS is no longer to be feared! At Flinders Medical Centre we routinely perform cerebral MRS using 2D multi-voxel PRESS CSI at an intermediate echo time (TE 135 ms). We have developed the following tips that have proven to work for a variety of pathologies and reduce operator dependence:

- Modify the volume of interest (VOI) size to best suit the lesion. We often use a 4 x 4 VOI to closely target a single lesion. Be sure to include some normal brain inside the VOI to aid in lesion diagnosis. A smaller VOI results in an improved shim and spectrum.
- Ensure the VOI avoids structures that will contaminate the baseline, such as skull, scalp, air, cerebrospinal fluid and major cerebral vessels.
- Do not be afraid to perform the spectroscopy in the coronal plane, particularly nearing the vertex.
- Ensure the VOI is planned according to an imaging slice. If not, perform a T2 localizer in the best plane and angle for the target lesion. Use 'copy image position' to ensure you have anatomical images during post-processing.
- Remember to use spatial saturation bands to cover the skull, scalp and vessels. We use six saturation bands positioned in 3D on all sides of the VOI. We found that if the saturation bands were positioned too close to the VOI we would get some baseline distortion. Leaving a buffer of one voxel's

Patient history

A 61-year-old female presented with a two week history of dysarthria and left sided weakness. Initial computed tomography (CT) scan revealed a faintly enhancing lesion within the right thalamus. MRI was performed to further characterize the lesion. The diagnosis of glioblastoma multiforme was confirmed with stereotactic biopsy.

Sequence details

Sagittal T1, axial PD, T2, T2 FLAIR, DWI, T1 and T1 post-gadolinium, coronal T2 and T1 post-gadolinium, 3D T1 MPRAGE post-gadolinium and multi-voxel PRESS MRS (TE 135 ms) were performed on our Siemens 1.5T MAGNETOM Aera scanner.

Imaging findings

A solitary, high T2 signal, intra-axial mass lesion is demonstrated within the right thalamus with mild surrounding vasogenic oedema (Fig. 1A). Multi-focal contrast enhancement is present (Fig. 1B). The MRS at an intermediate echo time (TE 135 ms) within the lesion clearly demonstrates a significant elevation of choline at 3.2 ppm relative to NAA at 2 ppm (Fig. 1C). This is in contrast to the normal MRS obtained from the left thalamus (Fig. 1D).

Discussion

Neoplasms display a characteristic MRS pattern, with an elevation of choline relative to NAA. This is the reverse of the normal situation in which NAA is the highest peak in the spectrum. Choline is a component of phospholipids and the increase in choline seen in neoplasms has been postulated to be the result of increased cell membrane turnover secondary to rapid cellular proliferation. A choline: NAA ratio of greater than 2.2 is highly suggestive of a neoplasm.

width between the saturation bands and the VOI improves this significantly.

- Ensure 'fully excited volume' is selected. This option helps to attain homogenous excitation of all metabolites within the VOI, whilst suppressing interference from outside the VOI.

This can be preset in your CSI protocol.

- Always perform MRS at the isocentre of the magnet.
- Ensure that your patient is comfortable, as their stillness is imperative.
- Post-processing is made easy through site defined defaults located in 'proto-

cols'. Here we have preset exactly what we wish our spectra to show, including range, scale and peak information. This significantly reduces variability between operators.

Case 2: Right cerebellar abscess

Patient history

A 62-year-old male presented with a three week history of headache, ataxia and diplopia. Initial CT scan revealed a ring enhancing lesion within the right cerebellar hemisphere. MRI was performed to further characterize the lesion. The diagnosis of a cerebral abscess was confirmed by the presence of pus at the time of operation and growth of *Staphylococcus aureus* on culture.

Sequence details

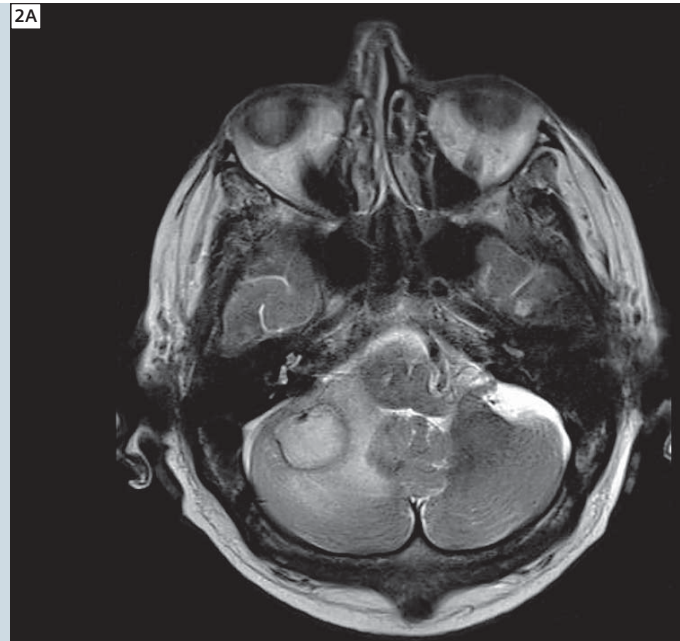
Sagittal T1 FLAIR, axial PD, T2, T2 FLAIR, DWI, T1 and T1 post-gadolinium, coronal T2 and T1 post-gadolinium, 3D T1 MPRAGE post-gadolinium and multi-voxel PRESS MRS (TE 135 ms) were performed on our Siemens 3T MAGNETOM Trio scanner.

Imaging findings

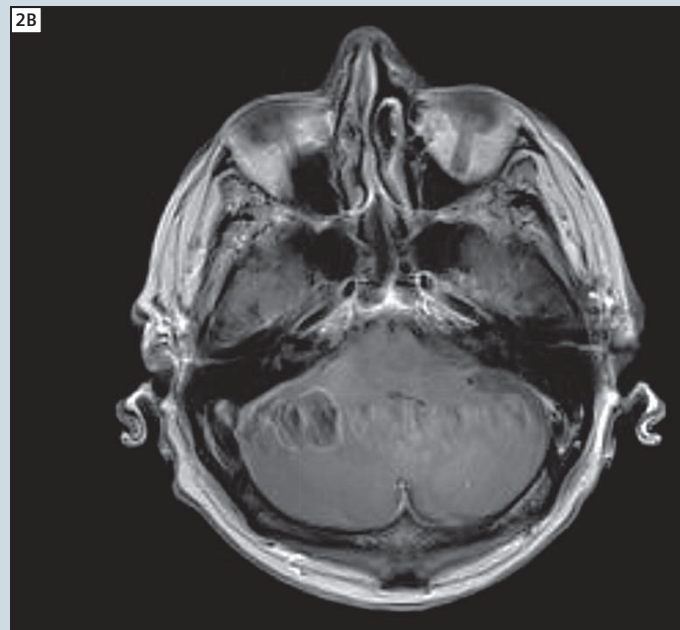A solitary, ring enhancing, high T2 signal, intra-axial mass lesion is demonstrated within the right cerebellar hemisphere with surrounding vasogenic oedema (Figs. 2A, B). Uniformly restricted diffusion is present within the lesion, being hyperintense on DWI and hypointense on the ADC map (Figs. 2C, D). The MRS at an intermediate echo time (TE 135 ms) clearly demonstrates an elevated lipid and lactate peak at 1.3 ppm (Fig. 2E). Importantly, there is no significant elevation of choline at 3.2 ppm relative to NAA at 2 ppm.

Discussion

Cerebral abscess characteristically demonstrates a significantly elevated lipid and lactate peak without an elevation of choline relative to NAA on MRS. This allows MRS to reliably distinguish between cerebral abscesses and neoplasms. The uniform restricted diffusion is also typical of cerebral abscess. Thus, the combination of MRS and DWI allows the diagnosis of a cerebral abscess to be made with a high degree of certainty.



2A T2w TSE axial.



2B T1w SE post intravenous gadolinium axial.

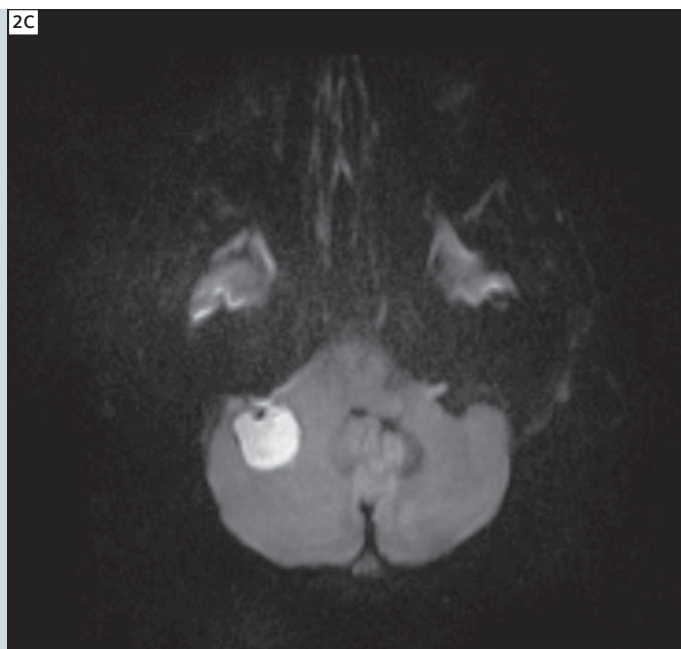MRS sequence details

The MRS sequence parameters for case 1, performed on our 1.5T MAGNETOM Aera were: 2D multi-voxel PRESS ^1H spectroscopy (csi_se_135), TR 1500 ms, TE 135 ms, 16 x 16 matrix, FOV 160 mm, slice thickness 15 mm,

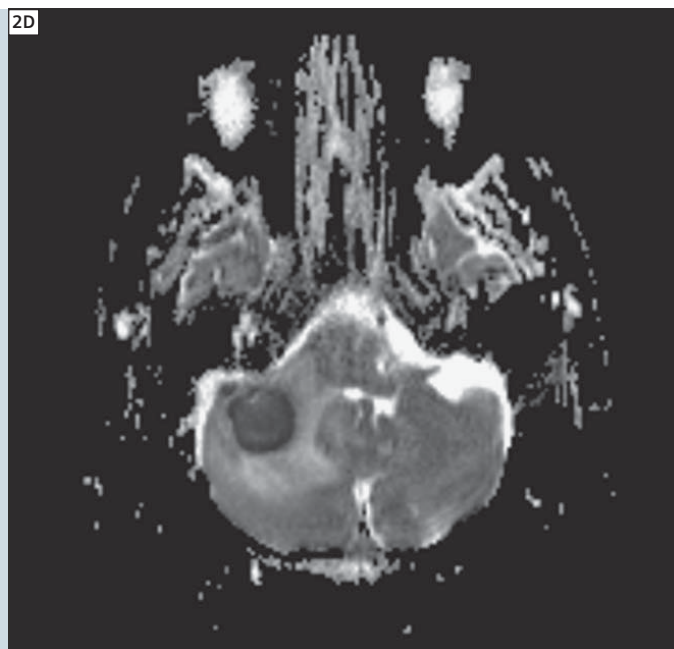
voxel size 10 x 10 x 15 mm, VOI 8 x 8, 4 averages, acquisition time 7:12 min.

The MRS sequence parameters for cases 2, 3 and 4, performed on our 3T MAGNETOM Trio were: 2D multi-voxel PRESS ^1H spectroscopy (csi_se_135 or

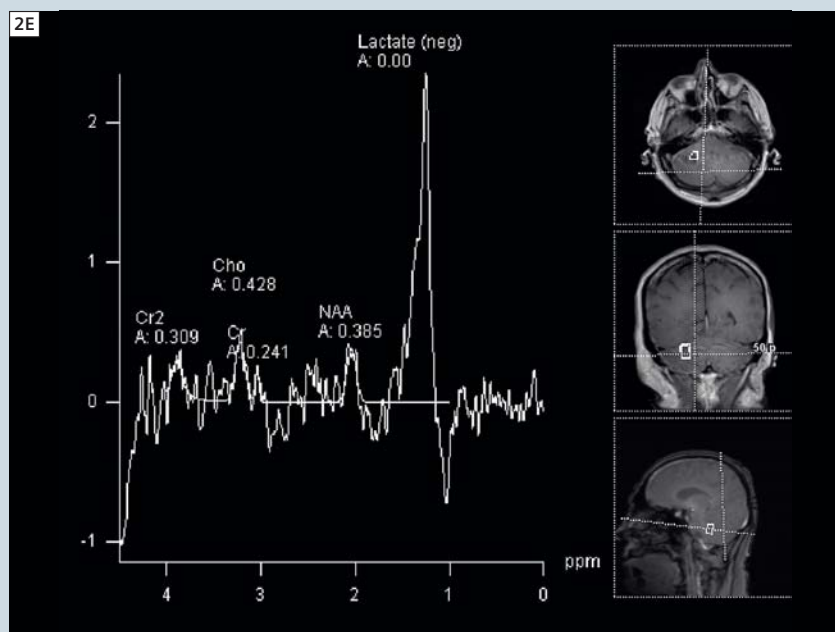
csi_se_270), TR 1700 ms, TE 135 ms or 270 ms, 16 x 16 matrix, FOV 160 mm, slice thickness 15 mm, voxel size 10 x 10 x 15 mm, VOI 4 x 4, 3 averages, acquisition time 6:53 min.



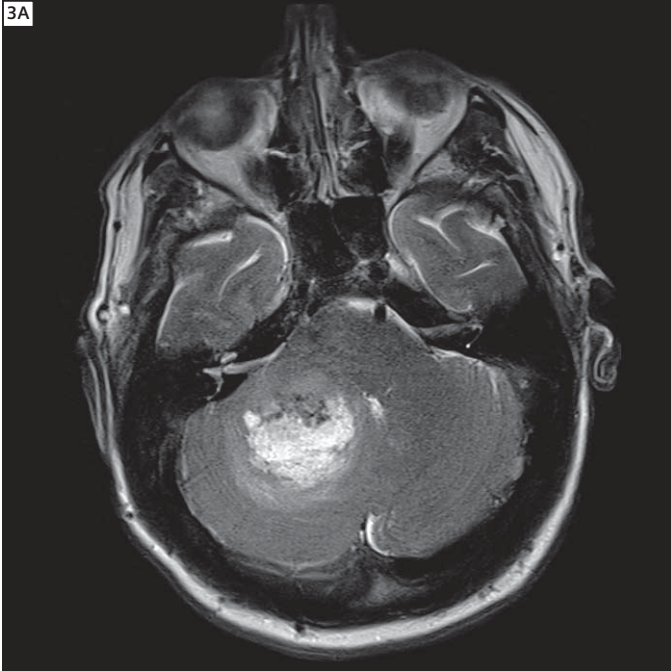
2C DWI axial.



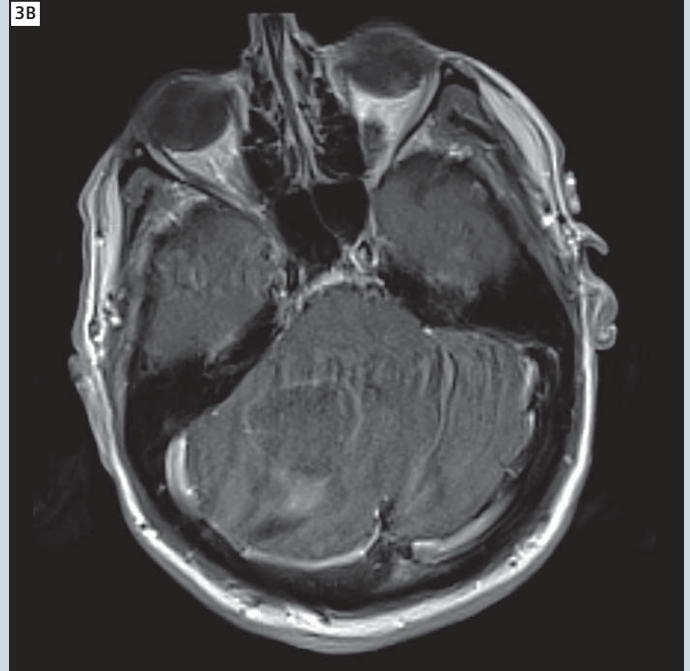
2D Corresponding ADC map.



2E Multi-voxel PRESS MRS (TE 135 ms) within the lesion in the right cerebellum.



3A T2w TSE axial.



3B T1w SE post intravenous gadolinium axial.

Case 3: Right cerebellar glioblastoma multiforme

Patient history

A 69-year-old male presented three days after a fall with progressively worsening headache. Initial CT scan revealed a ring enhancing lesion within the right cerebellar hemisphere. MRI was performed to further characterize the lesion. The diagnosis of glioblastoma multiforme was confirmed on excision biopsy.

Sequence details

Sagittal T1 FLAIR, axial PD, T2, T2 FLAIR, DWI, T1 and T1 post-gadolinium, coronal T2 and T1 post-gadolinium, 3D T1 MPRAGE post-gadolinium and multi-voxel PRESS MRS (TE 135 ms and TE 270 ms) were performed on our Siemens 3T MAGNETOM Trio scanner.

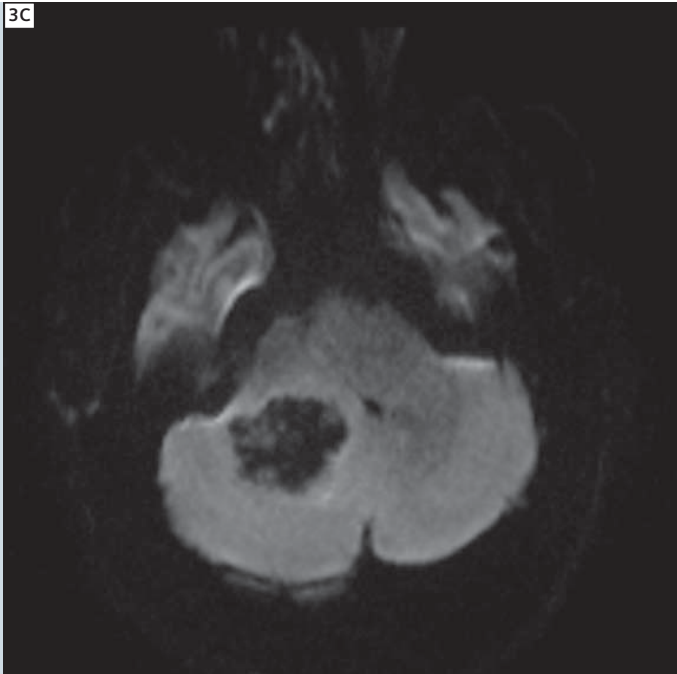Imaging findings

A solitary, slightly irregular, ring enhancing, high T2 signal, intra-axial mass lesion is demonstrated within the right cerebellar hemisphere with mild surrounding vasogenic oedema (Figs. 3A,

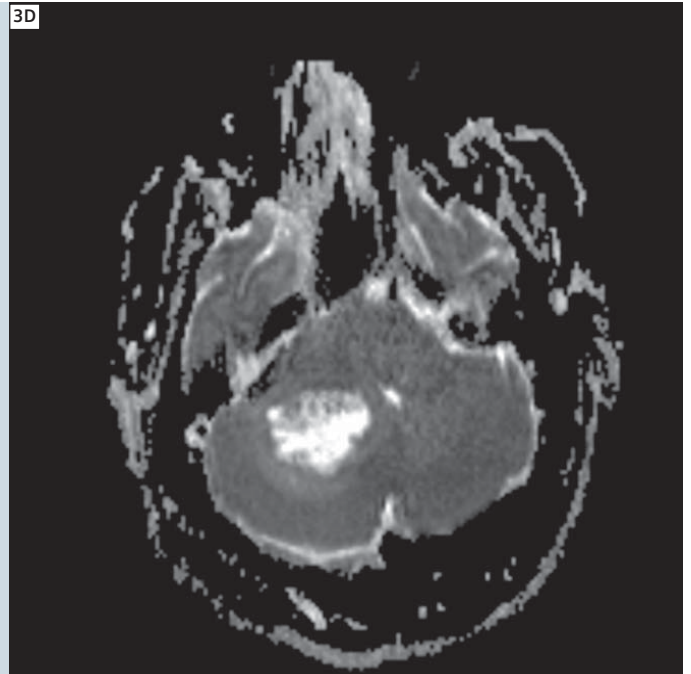
B). No restricted diffusion is present within the lesion, being hypointense on DWI and hyperintense on the ADC map, in keeping with T2 shine through (Figs. 3C, D). The MRS within the lesion, at a long echo time (TE 270 ms) clearly demonstrates a significant elevation of choline at 3.2 ppm relative to NAA at 2 ppm (Fig. 3E). An elevated lactate peak is also present at 1.3 ppm. The presence of lactate is confirmed with inversion of the peak when an intermediate echo time (TE 135 ms) is used (Fig. 3F). Importantly, MRS, at a long echo time (TE 270 ms) from white matter adjacent the lesion and largely outside of the surrounding vasogenic oedema, continues to demonstrate an abnormal elevation of choline relative to NAA (Fig. 3G).

Discussion

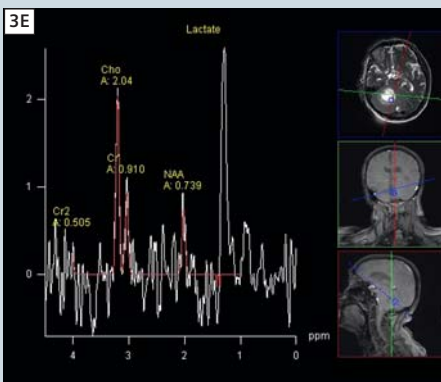
Magnetic resonance spectroscopy can be helpful in distinguishing a solitary primary cerebral neoplasm from a solitary cerebral metastatic deposit. The spectroscopic evaluation of the brain parenchyma outside of the lesion is the key in making this distinction. If, as in this case, there is an elevation of choline relative to NAA outside of the lesion, it is far more likely that the lesion represents a primary cerebral neoplasm. It is postulated that this is due to the infiltrative growth pattern of higher grade primary cerebral neoplasms. The lack of restricted diffusion in this case is in contrast to case 2.



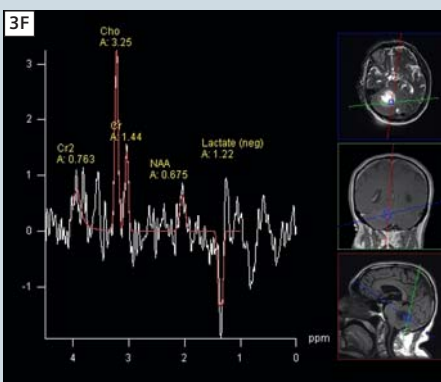
3C DWI axial.



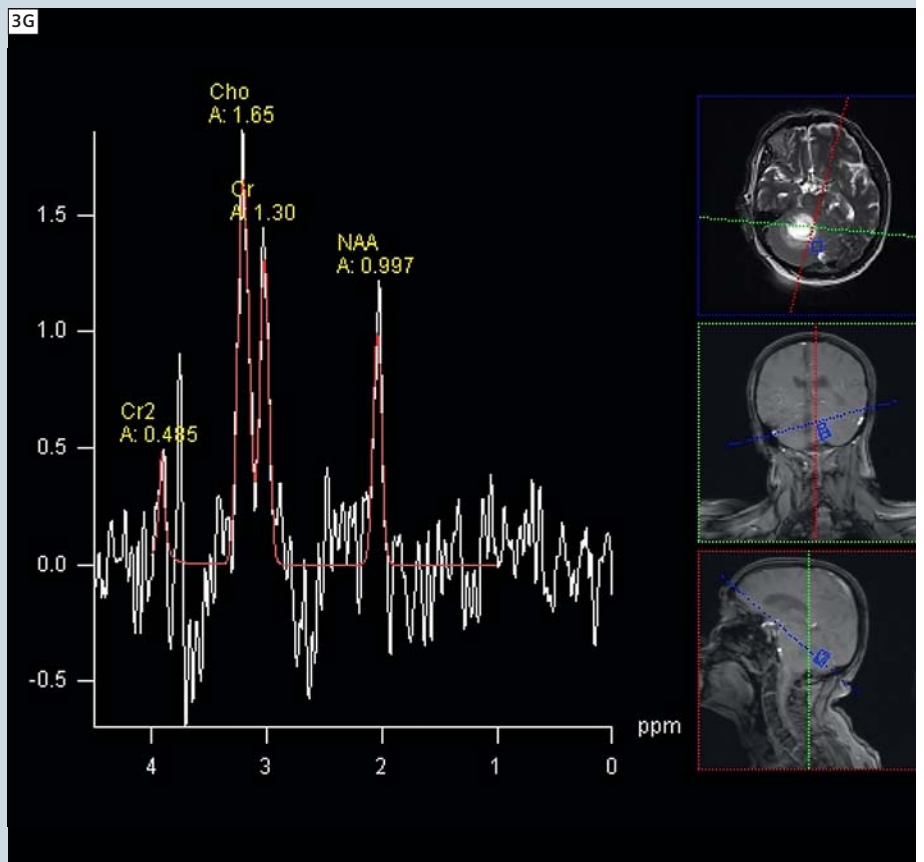
3D Corresponding ADC map.



3E Multi-voxel PRESS MRS (TE 270 ms) within the lesion in the right cerebellum.



3F Multi-voxel PRESS MRS (TE 135 ms) within the lesion in the right cerebellum.



3G Multi-voxel PRESS MRS (TE 270 ms) adjacent the lesion in the right cerebellum.

Case 4: Right frontal lobe metastases

Patient history

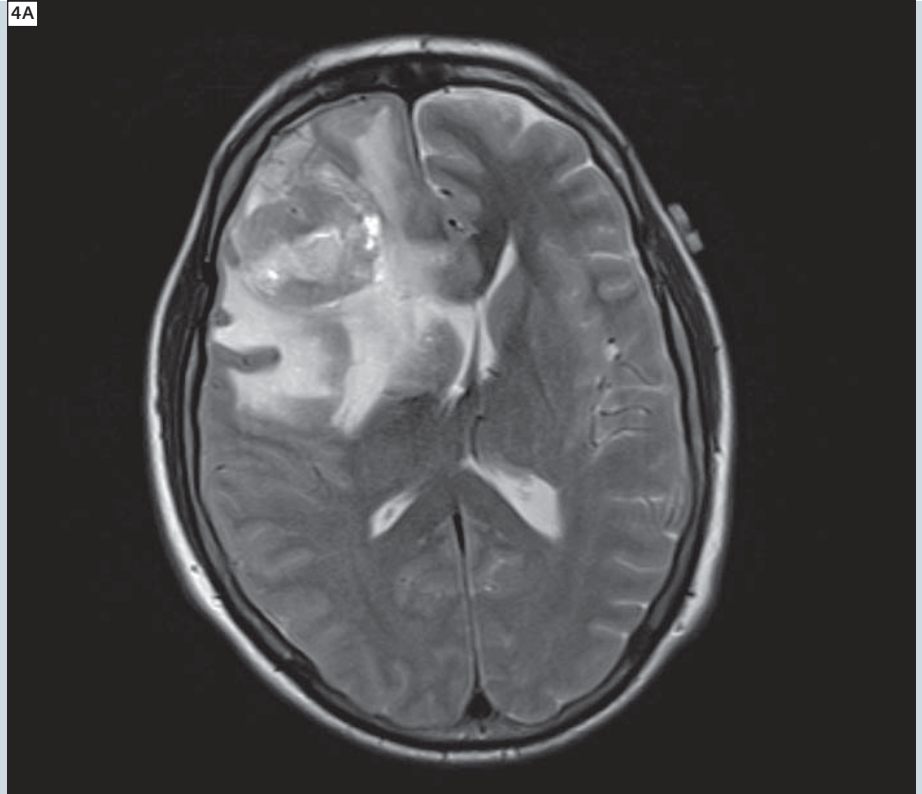
A 50-year-old male presented with a two week history of progressively worsening headache. Initial CT scan revealed a ring enhancing lesion within the right frontal lobe. MRI was performed to further characterize the lesion. The diagnosis of metastatic adenocarcinoma was confirmed on excision biopsy.

Sequence details

Sagittal T1 FLAIR, axial PD, T2, T2 FLAIR, DWI, T1 and T1 post-gadolinium, coronal T2 and T1 post-gadolinium, 3D T1 MPRAGE post-gadolinium and multi-voxel PRESS MRS (TE 135 ms) were performed on our Siemens 3T MAGNETOM Trio scanner.

Imaging findings

A solitary ring enhancing, heterogeneous T2 signal, intra-axial mass lesion is demonstrated within the right frontal lobe with extensive surrounding vasogenic oedema (Figs. 4A, B). The MRS within the lesion, at an intermediate echo time (TE 135 ms) clearly demonstrates a significant elevation of choline at 3.2 ppm relative to NAA at 2 ppm (Fig. 4C). An elevated lipid and lactate peak is also present at 1.3 ppm. Importantly, MRS, at an intermediate



4A T2w TSE axial.

echo time (TE 135 ms) from the white matter adjacent the lesion, within the surrounding vasogenic oedema, does not demonstrate an abnormal elevation of choline relative to NAA (Fig. 4D). A subsequently performed CT chest revealed a lobulated mass within the right upper lobe (Fig. 4E).

Discussion

In this case, the MRS from the brain parenchyma outside of the lesion does not demonstrate an elevation of choline relative to NAA, consistent with a solitary metastatic deposit. This is in contrast to case 3.

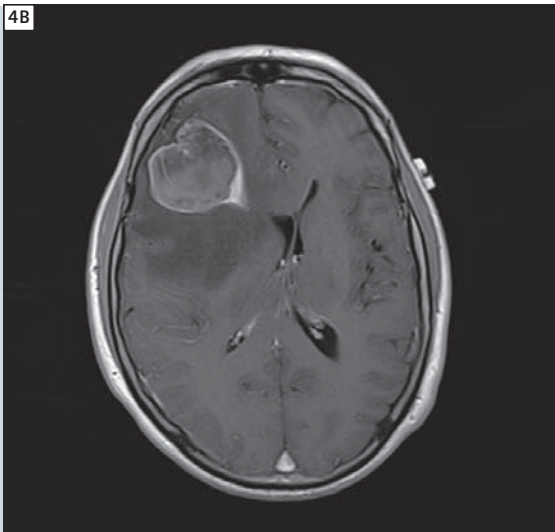
Case studies discussion

Magnetic resonance spectroscopy is a powerful technique that adds metabolic information to routine MRI brain examinations. As shown in these four cases, this additional information is useful in differentiating cerebral neoplasms from abscesses and distinguishing solitary primary cerebral neoplasms from solitary cerebral metastatic deposits. MRS is also beneficial in distinguishing

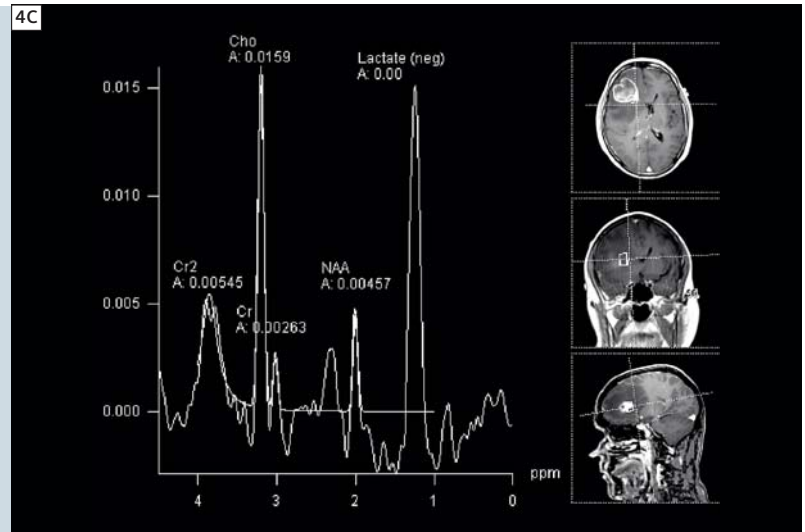
radiation necrosis from recurrent tumor, diagnosing metabolic and mitochondrial disorders such as MELAS (mitochondrial encephalopathy lactic acidosis and stroke like episodes) and guiding the biopsy of lesions. Recent improvements in scanner hardware and software allow MRS to be performed reliably and quickly, facilitating its incorporation into routine clinical practice.

References

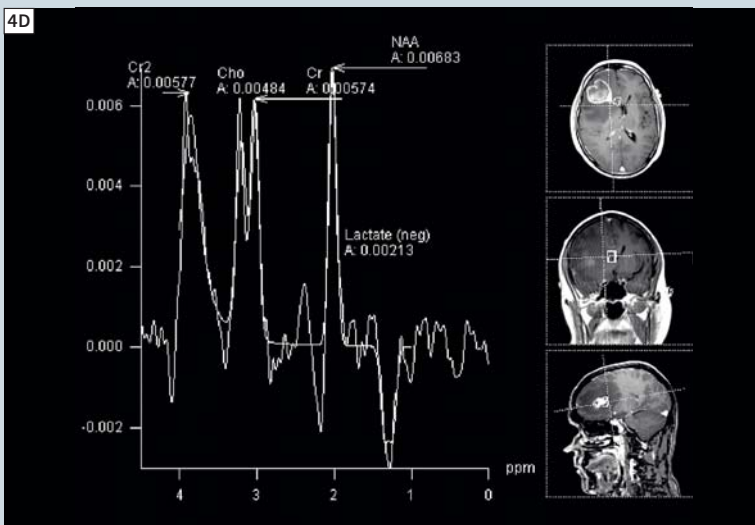
- 1 Horska A, Barker PB. Imaging of brain tumors: MR spectroscopy and metabolic imaging. *Neuroimag Clin N Am* 2010;20:293-310. Review.
- 2 Al-Okaili RN, Krejza J, Wang S, Woo JH, Melhem ER. Advanced MR imaging techniques in the diagnosis of intraaxial brain tumors in adults. *Radiographics* 2006;26:S173-S189. Review.
- 3 Barker PB, Bizzi A, De Stefano N, Gullapalli RP, Lin DDM. *Clinical MR spectroscopy: techniques and applications*. Cambridge University Press, Cambridge, 2010.



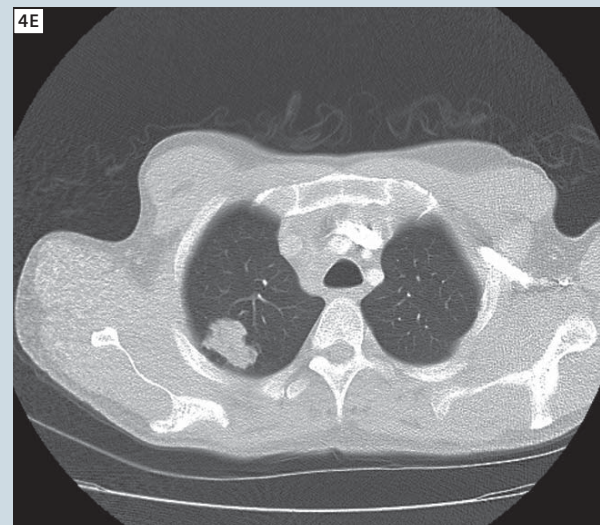
4B T1w SE post intravenous gadolinium axial.



4C Multi-voxel PRESS MRS (TE 135 ms) within the lesion in the right frontal lobe.



4D Multi-voxel PRESS MRS (TE 135 ms) adjacent the lesion in the right frontal lobe.



4E CT chest.

- 4 Gillard JH, Waldman AD, Barker PB. Clinical MR neuroimaging: diffusion, perfusion and spectroscopy. Cambridge University Press, Cambridge, 2004.
- 5 McRobbie DW, Moore EA, Graves MJ, Prince MR. MRI from picture to proton, 2nd edn. Cambridge University Press, Cambridge, 2007.
- 6 Meyerand ME, Pipas JM, Mamourian A, Tosteson TD, Dunn JF. Classification of biopsy-confirmed brain tumors using single-voxel MR spectroscopy. AJNR Am J Neuroradiol 1999;20:117–123.

- 7 Weybright P, Sundgren PC, Maly P, Hassan DG, Nan B, Rohrer S, Junck L. Differentiation between brain tumor recurrence and radiation injury Using MR spectroscopy. AJR 2005;185:1471–1476.
- 8 Burtcher IM, Skagerberg G, Geijer B, Englund E, Stahlberg F, Holtas S. Proton MR spectroscopy and preoperative diagnostic accuracy: an evaluation of intracranial mass lesions characterized by stereotactic biopsy findings. AJNR Am J Neuroradiol 2000;21:84–93.

Contact

Marc Agzarian BMBS(Hons), FRANZCR
Head of MRI
Division of Medical Imaging
Flinders Medical Centre
Bedford Park, South Australia, 5041
Australia
Phone: +61 8 8204 4405
marc.agzarian@health.sa.gov.au

Angela Walls M.MedSc, B.App.Sc.Med Rad.
Head MRI Radiographer
Division of Medical Imaging
Flinders Medical Centre
Bedford Park, South Australia, 5041
Australia
Phone: +61 8 8204 5750
angela.walls@health.sa.gov.au