

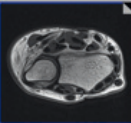
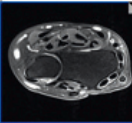
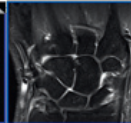
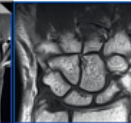
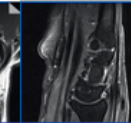
NOTE

This protocol was provided by
**Prof. Michael Recht, NYU
 School of Medicine**, Dep. of
 Radiology, NY, USA, on behalf of
 the MSK Advisory Board


contrast:
 sequence type:
 slice orientation:

acquisition time
 resolution [mm³]:
 matrix [Px2]:
 bandwidth (Hz/Px):
 turbo factor:
 TR [ms]:
 TE [ms]:
 TI [ms]:
 field of view [mm]:

2D SCAN

PD TSE	PD TSE	PD TSE	T1 TSE	PD TSE
transversal	transversal	coronal	coronal	sagittal
				
03:21	03:25	03:25	02:57	03:25
0.3x0.3x3.0	0.3x0.3x3.0	0.3x0.3x3.0	0.3x0.3x3.0	0.3x0.3x3.0
256x256	256x256	256x256	256x256	256x256
130	130	260	130	130
8	8	8	4	8
3800	3800	3800	550	3800
39	39	39	13	39
80	80	80	80	80

3D SCAN

T2 MEDIC
coronal

03:28
0.3x0.3x1.0
256x256
170
32
18
80

clinical requests

general
injury intrinsic ligaments
 osseous
 tendons
 ECU instability
carpal tunnel
AVN

total scan time [min:s]

2D scan → 16:33
 09:47
 09:47
 09:47
 09:47
 09:47
 09:47
 09:47

pd_tse_tra	pd_tse_fs_tra	pd_tse_fs_cor	t1_tse_cor	pd_tse_fs_sag	t2_me3d_we_cor
	pd_tse_fs_tra	pd_tse_fs_cor	t1_tse_cor		
	pd_tse_fs_tra	pd_tse_fs_cor	t1_tse_cor		
	pd_tse_fs_tra	pd_tse_fs_cor	t1_tse_cor		
	pd_tse_fs_tra	pd_tse_fs_cor	t1_tse_cor		
	pd_tse_fs_tra	pd_tse_fs_cor	t1_tse_cor		
	pd_tse_fs_tra	pd_tse_fs_cor	t1_tse_cor		
	pd_tse_fs_tra	pd_tse_fs_cor	t1_tse_cor		

MAGNETOM Avanto Wrist Protocol

www.siemens.com/magnetom-world

SIEMENS