

Perspective – High Potential Impact of Simultaneous Multi-Slice Diffusion Acquisition Strategies on Future Clinical Neuroradiology Practice

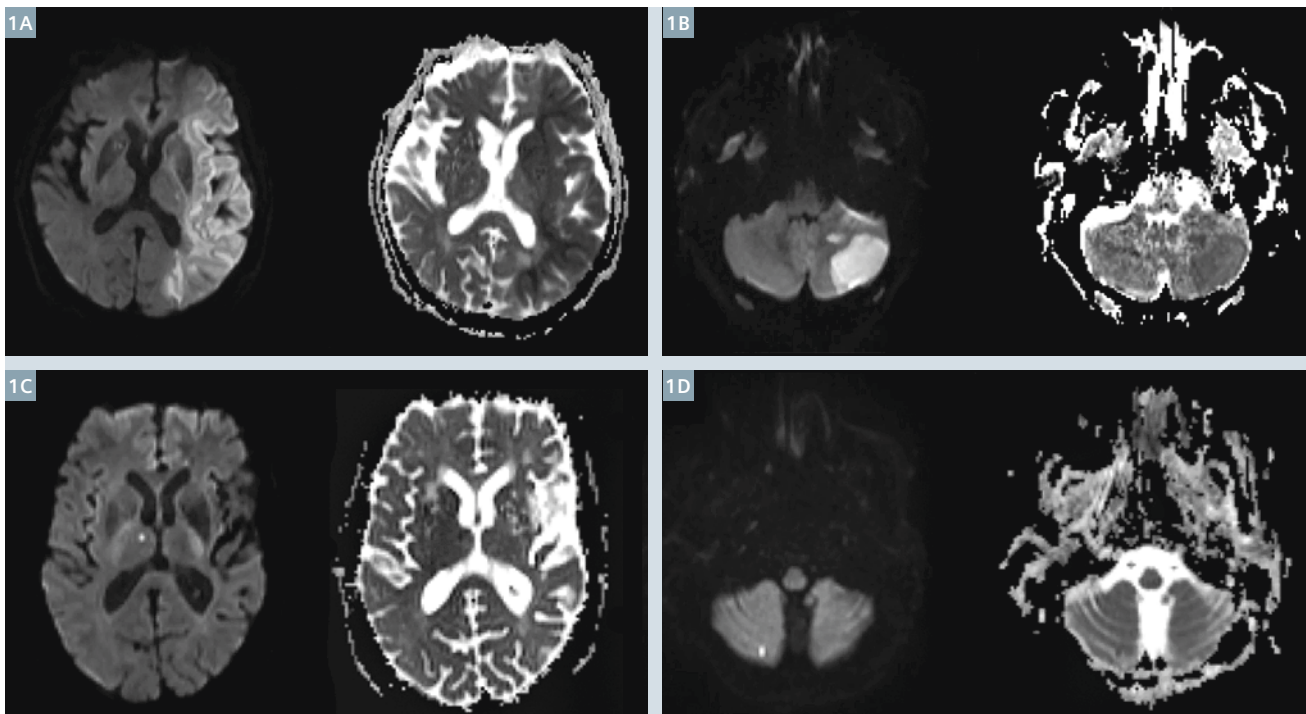
Timothy Shepherd, M.D., Ph.D.

Assistant Professor, Neuroradiology Section, Department of Radiology, New York University, New York, NY, USA

Diffusion has become a critical component of almost all neuroradiology protocols for the head [1] with potential important roles in spine and neck now being better defined [2, 3]. The most impactful application over the past 25 years has been that diffusion is essential for the diagnosis of acute stroke, a frequent indication for MRI in hospitals throughout the world. Diffusion MRI also helps determine subsequent clinical management decisions in this

stroke population [1]. Tissue diffusion properties can be informative for characterizing a variety of other neurological conditions such as perioperative or drug-related cytotoxic edema, specific tumor diagnoses (e.g. epidermoid) and tumor grading (e.g. lymphoma) [4]. Early mathematical models of diffusion anisotropy that are widely available for clinical use, such as diffusion tensor imaging (DTI), can be used to indirectly assess white matter

integrity. DTI can characterize white matter pathology not evident or readily detected with other conventional MRI sequences (e.g. normal-appearing white matter in multiple sclerosis) [5]. DTI data can be used to create tractography estimations for localizing eloquent white matter pathways, such as the arcuate fasciculus, for preoperative surgical planning of anatomic corridors and extent of resection [6].



1 Simultaneous multi-slice axial diffusion trace and apparent diffusion coefficient maps in 4 different clinical patients with ischemic infarcts – large left middle cerebral artery territory (**1A**), left anterior inferior cerebellar territory (**1B**), right thalamus (**1C**) and right peripheral cerebellar hemisphere (**1D**). Note while there was a small drop in apparent signal-to-noise in the posterior fossa using SMS diffusion with a 20-channel head & neck coil, large and small, focal posterior fossa infarcts remain well-delineated (panels 1B, D respectively).

For current routine clinical imaging, diffusion trace and apparent diffusion coefficient (ADC) maps have proven most efficient and practical – these generally only require 3 or 6 diffusion encoding directions for sufficient accuracy during qualitative clinical interpretation. Such scans can be acquired in 2-3 minutes on most modern MRI scanners, whereas DTI for tractography purposes can require 10+ minute acquisitions. More recent acquisition strategies and their companion advanced data analysis techniques developed over the past 15 years provide more information about the tissue environment than diffusion trace or DTI-derived parameters, yet remain relatively limited to application in volunteers and/or selected patient populations under carefully controlled conditions. Such sophisticated techniques require longer acquisitions to increase the number of gradient directions, increase spatial resolution, and/or to acquire images at multiple diffusion-weightings (e.g., b-values of 1500-4000 s/mm²). These acquisitions result in lower signal-to-noise ratio (SNR) that also can require more signal averages. Scan time for such acquisitions is largely affected by image geometry (number of slices and resolution/matrix size), number of averages and diffusion encoding directions [7], but quickly approaches 15-30 minutes, making it impractical for use in most sick patients. Thus, higher angular resolution diffusion acquisition strategies [8, 9], measures of non-Gaussian diffusion [10], advanced biophysical modeling [11, 12, 13] and high spatial resolution diffusion studies of cortical and hippocampal layers [14, 15] have shown exciting potential utility for studying nervous tissue in disease that is thus far unrealized in daily clinical practice.

Recently, simultaneous multi-slice (SMS) acquisition with a blipped-CAIPIRINHA readout has demonstrated the potential to reduce scan times for 2D multislice diffusion EPI [16, 17]. This technique relies on exciting multiple slices simultaneously and reconstructing them individually using the slice GRAPPA method. Since multiple slices are excited simultaneously, the

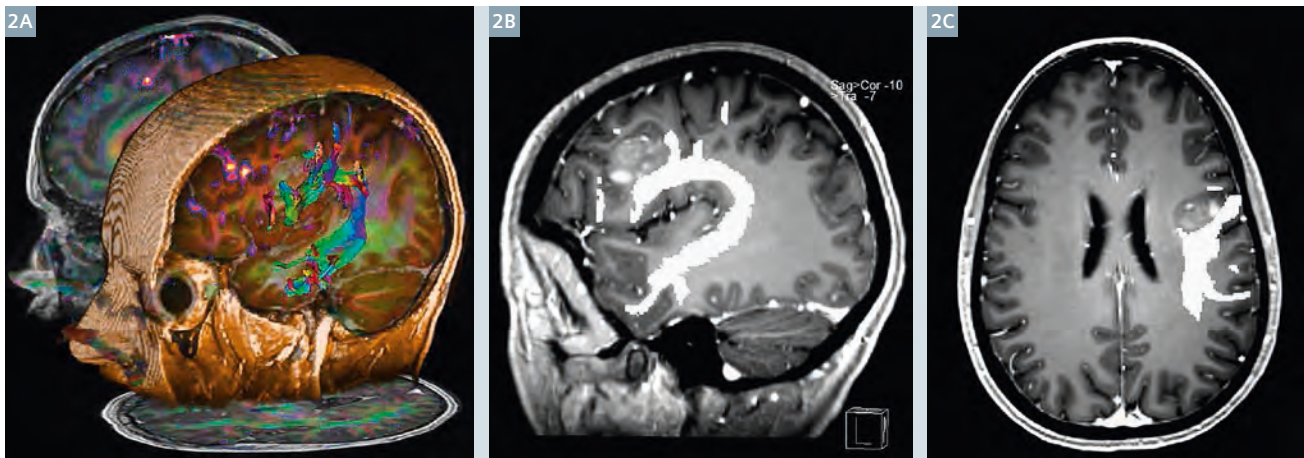
overall repetition time (TR) for a desired spatial coverage can be reduced. The SMS acceleration method is SNR preserving with no intrinsic reduction in signal due to reduced sampling. The only SNR penalty is due to g-factor related losses during slice GRAPPA reconstruction. In simple terms for practicing radiologists like myself, this new SMS technology allows us to acquire the same diffusion data for a variety of clinical and translational research applications using a much shorter TR and shortened overall scan time. Alternatively SMS can be used to increase slice resolution and/or increase the overall volume of coverage in the same scan time.

At our institution, we were quick to recognize the potential practical workflow advantages for SMS diffusion to reduce scan time requirements in our patient population. In our initial explorations of the SMS diffusion application in healthy volunteers, we learned that one must pay particular attention to correct fat saturation. With single-shot EPI, an unsaturated fat signal affects only a single slice. With SMS, there is potential for aliasing into all simultaneously acquired slices. With TR reduction below 2.5 seconds, factors such as increased acoustic noise may make patients less comfortable. We also noted that SMS trace images have more T1-weighting than we were used to seeing – this ‘T1-shine through’ is most evident in the limbic cortical regions and in the central portions of the cortical spinal tract as it descends through the hemispheric white matter away from the hand knob region. We directly compared the axial diffusion sequence for our routine MRI head protocol to an SMS version with acceleration factor of 2 and a TR reduced by 50%. Scans were performed on a MAGNETOM Skyra 3T (Siemens Healthcare, Erlangen, Germany) with a Head/Neck 20 coil. With the calibration scan required for the SMS reconstructions, scan time was reduced approximately 40%, thereby saving 1 minute per scan. Given that a diffusion-weighted sequence is present in almost all neuroradiology protocols, this 1 minute

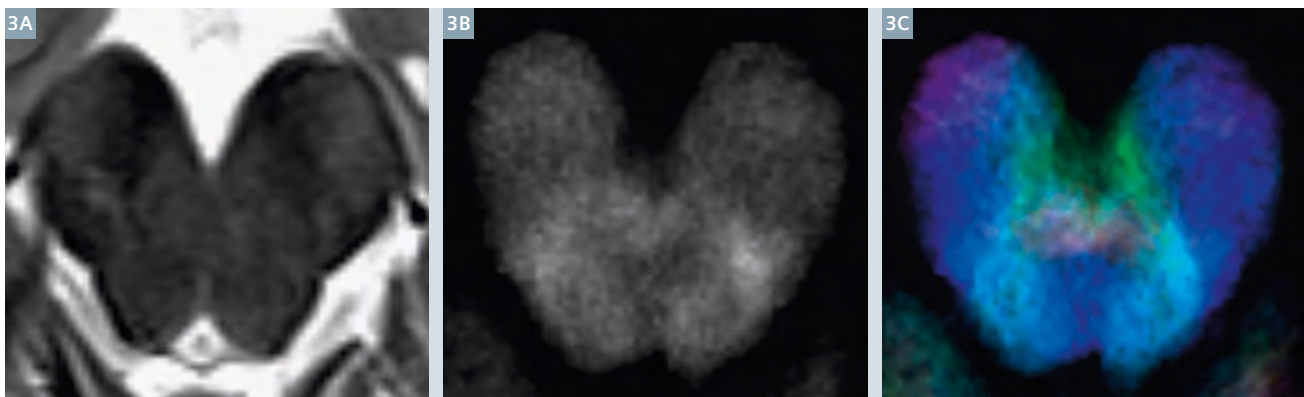
time savings would translate into sufficient time for an additional 2-3 patient scans per day per magnet at a busy outpatient practice. Similar results are expected for coronal diffusion acquisitions although this is not a part of our institution’s routine protocols. Further time savings might be realized with 3 or 4-fold slice acceleration using array coils with more receive elements (such as a Siemens 64-channel head and neck coil). In a blinded side-by-side comparison, 3 neuroradiologists universally agreed that image quality was equivalent between the routine and SMS-accelerated axial diffusion trace sequence and calculated ADC images such that the latter was acceptable for routine clinical work (see examples in Fig. 1).

Next we compared diffusion tensor imaging and deterministic tractography for presurgical planning cases – again, side-by-side comparison of data obtained with SMS acceleration factor of 2 appeared equivalent and appropriate for use in clinical care. Tractography results for the corticospinal tract and arcuate fasciculus in close proximity to various ipsilateral intra-axial neoplasms were equivalent for routine and SMS-based high angular resolution diffusion acquisitions (see example in Fig. 2). Our referring neurosurgeons have been very happy with the resulting data and have used SMS-derived tractography as part of their routine workflow on a weekly basis for surgical planning over the past 9 months. Thus far, we have scanned over 1000 patients with MRI head protocols using SMS diffusion without problems or patient recalls for diffusion image quality. The initial results of these comparisons were reported at RSNA last year [18] and a more detailed report has been submitted for publication.

Completing routine clinical scans faster has many practical advantages for patients and radiology administrators, but what I personally am most excited about is the potential for SMS-accelerated diffusion to enable more translational research in patient populations with advanced diffusion acquisition and postpro-



- 2 Deterministic diffusion tensor tractography of the arcuate fasciculus based on a simultaneous multi-slice diffusion dataset from a left-language dominant patient with a left frontal operculum high-grade glioma (2A: 3D lateral projection of tracts on MPRAGE with overlay from fMRI word generation task). Oblique sagittal and axial 2D reformats (2B, C respectively) demonstrate that the tumor margin abuts the inferior and medial margins of the tractography-visualized frontal projections of the arcuate fasciculus. Over the past year we have consistently obtained excellent tractography results for presurgical planning patients using SMS diffusion acquisition strategies – the accelerated acquisition quickly provides a diffusion dataset with high angular resolution, reduces patient motion problems and leaves more available scan time for detailed functional MRI assessment of eloquent cortex.



- 3 Short scan times enabled by simultaneous multi-slice diffusion should facilitate more frequent clinical use or implementation of advanced diffusion acquisitions and postprocessing. Here an example of caudal midbrain anatomy depicted with conventional axial T2 (3A), track density images (3B) and direction-encoded track density (3C). This advanced diffusion technique requires high angular resolution diffusion acquisitions (64 directions, $b = 2500 \text{ s/mm}^2$), but can be acquired with SMS approaches in under 10 minutes. Exquisite anatomical detail is obtained and may be exploited in the future for new biomarkers of brainstem pathology and functional neurosurgery planning [for details see 19-21].

cessing strategies. Frankly, most patients, particularly elderly sick patients, will not tolerate individual scan sequence scan times beyond 8-10 minutes well. SMS acquisition strategies finally may allow us to apply advanced diffusion strategies reported at research meetings to *real* patients. As an example, over the past 6 months, we have been using SMS-diffusion acquisition strategies to acquire high angular resolution

multiple b -shell scans for diffusion kurtosis imaging and advanced models of mesoscopic tissue structure in over 500 patients as part of an NIH-funded study – it would not be practical to include this acquisition using conventional diffusion acquisitions because of scan time and workflow limitations on our busy clinical scanners. We also use SMS to obtain diffusion data sufficient for super-resolution tract density imaging (TDI)

[19] to define thalamic substructures for functional neurosurgery planning in patients with essential tremor and Parkinson's disease [20]. Recent results indicate SMS diffusion acquisitions combined with TDI can reveal internal brainstem anatomy not previously seen in living patients using 3T MRI [21] (see examples in Fig. 3). These latter two results from our group suggest neuroradiologists may need to relearn detailed anatomy

for deep gray nuclei and brainstem structures that were previously considered difficult or impossible to visualize outside autopsy. Such studies also could lead to direct targeting opportunities in the future for functional neurosurgery applications.

Finally, it should be emphasized that the best models of human pathology are living human patients! The present difficulty studying real patients with long diffusion scan times has so far limited application of advanced biophysical models of tissue mesoscopic structure derived from diffusion data to cooperative, motivated outpatients with chronic conditions, animal models of human disease, and *ex vivo*, formaldehyde-fixed samples, where many water diffusion and relaxation properties are altered [22, 23]. I personally anticipate that SMS diffusion techniques will provide a substantial new window of opportunity to study many new patient populations with both acute and chronic pathologies directly – this should result in improved understanding of human neurologic diseases, such as the nervous tissue changes associated with acute stroke. SMS appears to represent a transformative technology for translating advanced diffusion MRI applications into clinical practice.

References

- Schaefer PW, Grant PE, Gonzalez RG. Diffusion-weighted MR imaging of the brain. *Radiology* 2000; 217(2): 331-345.
- Andre JB, Zaharchuk G, Saritas E, et al. Clinical evaluation of reduced field-of-view diffusion-weighted imaging of the cervical and thoracic spine and spinal cord. *Am J Neuroradiol* 2012; 33(10): 1860-1866.
- Thoeny HC. Diffusion-weighted MRI in head and neck radiology: applications in oncology. *Cancer Imaging* 2011; 10: 209-214.
- Barajas RF Jr, Rubenstein JL, Chang JS, Hwang J, Cha S. Diffusion-weighted MR imaging derived apparent diffusion coefficient is predictive of clinical outcome in primary central nervous system lymphoma. *Am J Neuroradiol* 2010; 31(1): 60-66.
- Mesaros S, Rocca MA, Kacar K, et al. Diffusion tensor MRI tractography and cognitive impairment in multiple sclerosis. *Neurology* 2012; 78(13): 969-975.
- Wu JS, Zhou LF, Tang WJ, et al. Clinical evaluation and follow-up outcome of diffusion tensor imaging-based functional neuronavigation: a prospective, controlled study in patients with gliomas involving pyramidal tracts. *Neurosurgery* 2007; 61(5): 935-948.
- Mukherjee P, Chung SW, Berman JI, Hess CP, Henry RG. Diffusion tensor MR imaging and fiber tractography: technical considerations. *Am J Neuroradiol* 2008; 29(5): 843-852.
- Tuch DS. Q-ball imaging. *Magn Reson Med* 2004; 52(6): 1358-1372.
- Wedeen VJ, Hagmann P, Tseng WY, Reese TG, Weisskoff RM. Mapping complex tissue architecture with diffusion spectrum magnetic resonance imaging. *Magn Reson Med* 2005; 54(6): 1377-1386.
- Jensen JH, Helpert JA. MRI quantification of non-Gaussian water diffusion by kurtosis analysis. *NMR Biomed* 2010; 23(7): 698-710.
- Assaf Y, Freidlin RZ, Rohde GK, Bassar PJ. New modeling and experimental framework to characterize hindered and restricted water diffusion in brain white matter. *Magn Reson Med* 2004; 52(5): 965-978.
- Zhang H, Schneider T, Wheeler-Kingshott CA, Alexander DC. NODDI: Practical in vivo neurite orientation dispersion and density imaging of the human brain. *Neuroimage* 2012; 61(4): 1000-1016.
- Fieremans EJ, Jensen JH, Tabesh A, Hu C, Helpert JA. White matter model for diffusional kurtosis imaging. Paper presented at: ISMRM 2010. Proceedings of the 18th Annual Meeting of the International Society for Magnetic Resonance in Medicine: 2010 May 1-7; Stockholm, Sweden.
- McNab JA, Polimeni JR, Wang R, et al. Surface based analysis of diffusion orientation for identifying architectonic domains in the in vivo human cortex. *Neuroimage* 2013; 69: 87-100.
- Shepherd T, Ozarslan E, Yachnis AT, King MA, Blackband SJ. Diffusion tensor microscopy indicates the cytoarchitectural basis for diffusion anisotropy in the human hippocampus. *Am J Neuroradiol*; 28(5): 958-964.
- Setsompop K, Gagoski BA, Polimeni JR, Witzel T, Wedeen VJ, Wald LL. Blipped-controlled aliasing in parallel imaging for simultaneous multislice echo planar imaging with reduced g-factor penalty. *Magn Reson Med* 2012; 67(5): 1210-1024.
- Xu J, Moeller S, Auerbach EJ, et al. Evaluation of slice accelerations using multiband echo planar imaging at 3T. *Neuroimage* 2013; 83: 991-1001.
- Young MG, Cohen BA, Glielmi C, et al. Multiband sequence reduces scan time for diffusion MRI and tractography in clinical patients. Paper presented at: RSNA 2014. Proceedings of the 100th Scientific Assembly and Annual Meeting of the Radiological Society of North America; 2014 Nov 30 – Dec 5; Chicago, USA.
- Calamante F, Tournier JD, Jackson GD, Connelly A. Tract density imaging (TDI) : super-resolution white matter imaging using whole-brain track density mapping. *Neuroimage* 2010; 53(4): 1233-1243.
- Shepherd TM, Chung S, Glielmi C, Mogilner AY, Boada F, Kondziolka D. 3-Tesla magnetic resonance imaging track density imaging to identify thalamic nuclei for functional neurosurgery. Paper presented at: CNS 2014. Proceedings of the 63rd Annual Congress of Neurological Surgeons; 2014 Oct 18-22; Boston, USA.
- Hoch M, Chung S, Yoshimoto A, Ben-Eliezer N, Fatterpekar G, Shepherd TM. Advanced multiparametric MRI reveals detailed in vivo brainstem anatomy at 3-T. Paper presented at: ASNR 2015. Proceedings of the 53rd Annual Meeting of the American Society of Neuroradiology; 2015 Apr 25-30; Chicago, USA.
- Shepherd TM, Flint JJ, Thelwall PE., et al. Postmortem interval alters the water relaxation and diffusion properties of rat nervous tissue – implications for MRI studies of human autopsy samples. *Neuroimage* 2009; 44(3): 820-826.
- Shepherd TM, Thelwall PE, Stanisz GJ, Blackband SJ. Aldehyde fixative solutions alter the water relaxation and diffusion properties of nervous tissue. *Magn Reson Med* 2009; 62(1): 26-34.

Contact

Timothy Shepherd
 NYU School of Medicine
 NYU Langone Medical Center
 Department of Radiology
 660 First Avenue
 New York, NY 10016
 USA
 Phone: +1 212/263-8487
 Timothy.Shepherd@nyumc.org

