

Right-sided Aortic Arch with Aberrant Left Subclavian Artery from Kommerell's Diverticulum

By KG Srinivasan, MD
KGS Advanced MR and CT Scan, Madurai, Tamil Nadu, India

History

A 38-year-old female patient, complaining of occasional breathlessness and dyspnea upon exertion, presented herself to the hospital. A thoracic CT angiography (CTA) was requested for further investigation.

Diagnosis

CTA images showed a right-sided aortic arch with the thoracic aorta descending along the right side of the spine and an aberrant left subclavian artery rising from the Kommerell's diverticulum (Figs. 1a–1e). The branches of the right-sided aortic arch, from proximal to distal were the left common carotid, innominate and left subclavian arteries. The Kommerell's diverticulum was situated posteriorly to the trachea and esophagus forming a vascular ring (Figs. 1a, 1b, and 1d). The right principal bronchus was compressed by the right pulmonary artery and the right-sided descending aorta (Fig. 1f).

All pulmonary vessels were clear, showing no evidence of pulmonary embolism (PE).

Comments

The diverticulum is the remnant of the left fourth aortic arch and was original-

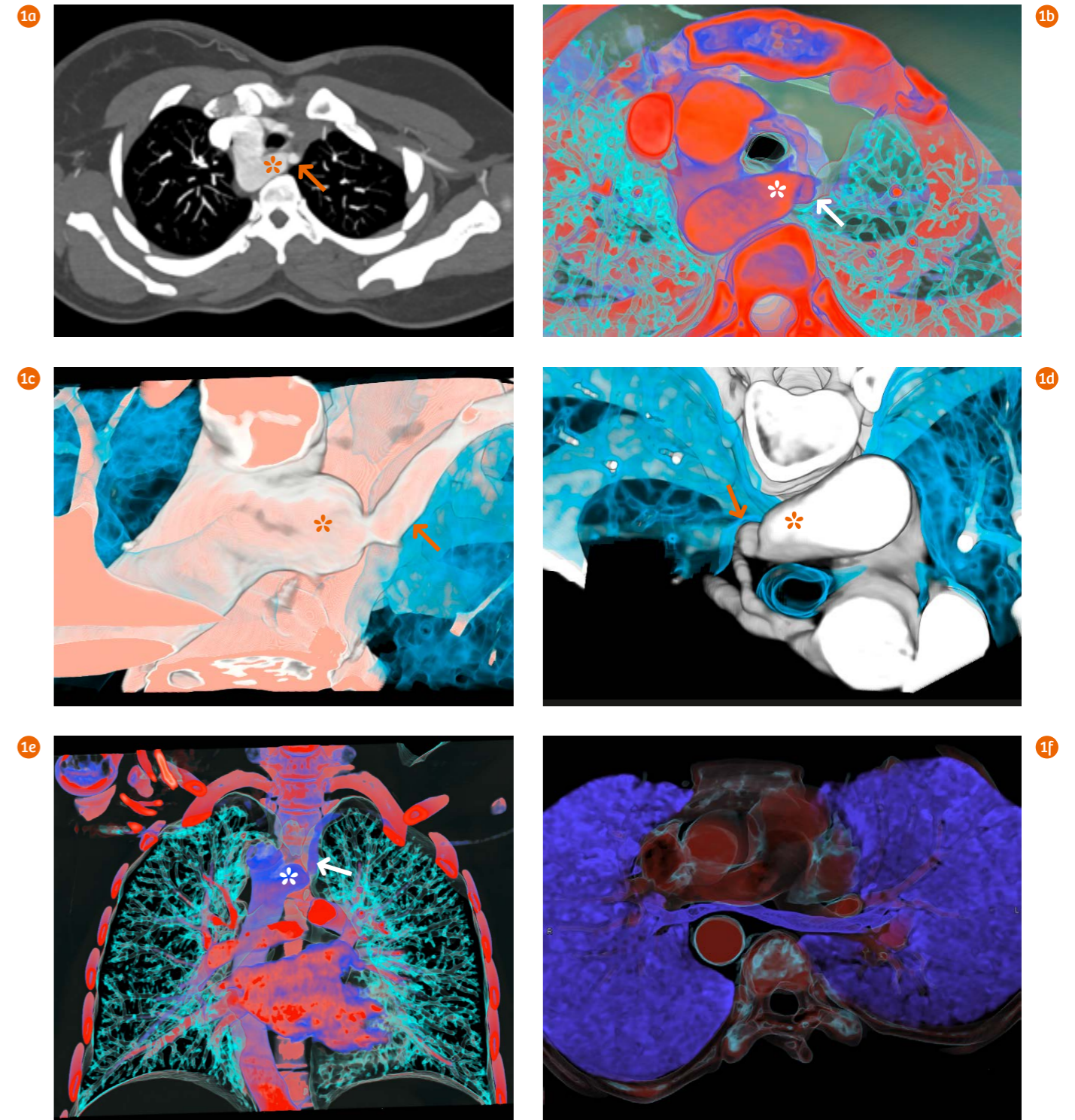
ly described by Burckhard Friedrich Kommerell in 1936. The aberrant left subclavian artery usually originates from a Kommerell's diverticulum. Patients with right-sided aortic arch and aberrant subclavian artery might have symptoms related to the presence of the vascular ring. In this case, there was additional evidence of the compressed right principal bronchus

suggesting that the patient's symptoms were related to the vascular variations. The combination of 80 kV and sub-mm collimation was applied to obtain high quality CTA images with reduced radiation dose and amount of contrast agent. This is especially valuable for visualizing small distal vessels, helping the physician to rule out small peripheral PEs. ●

Examination Protocol

Scanner	SOMATOM go.Now		
Scan area	Thorax	Rotation time	0.8 s
Scan mode	Spiral	Pitch	1.5
Scan length	199 mm	Slice collimation	16 × 0.7 mm
Scan direction	Cranio-caudal	Slice width	1.5 mm
Scan time	9.2 s	Reconstruction increment	1.0 mm
Tube voltage	80 kV	Reconstruction kernel	Br40
Effective mAs	164 mAs	Contrast	350 mg/mL
Dose modulation	CARE Dose4D™	Volume	50 mL + 40 mL saline
CTDI _{vol}	5.17 mGy	Flow rate	5 mL/s
DLP	115 mGy cm	Start delay	Bolus tracking + 4 s
Effective dose	1.6 mSv		

The outcomes by Siemens' customers described herein are based on results that were achieved in the customer's unique setting. Since there is no "typical" hospital and many variables exist (e.g., hospital size, case mix, level of IT adoption), there can be no guarantee that other customers will achieve the same results.



1 Axial (Fig. 1a) and VRT images (Figs. 1b–1f) show a right-sided aortic arch with the thoracic aorta descending along the right side of the spine (Fig. 1e), and an aberrant left subclavian artery (Figs. 1a–1e, arrows) rising from the Kommerell's diverticulum (Figs. 1a–1e, asterisk), which is posterior to the trachea and esophagus forming a vascular ring. The right principal bronchus is compressed by the right pulmonary artery and the right-sided descending aorta (Fig. 1f).