

# Permeability Imaging of Parotid Tumors with Golden-Angle Radial Sparse Parallel MR Imaging (GRASP)

Sohil H. Patel, M.D.<sup>1</sup>; Hersh Chandarana, M.D.<sup>1</sup>; Kai Tobias Block, Ph.D.<sup>1</sup>; Robert Grimm, Ph.D.<sup>2</sup>; Girish Fatterpekar, M.D.<sup>1</sup>

<sup>1</sup>Department of Radiology, NYU Langone Medical Center, New York, NY, USA

<sup>2</sup>Siemens Healthcare, Erlangen, Germany

## Introduction

A range of pathologic processes may affect the parotid gland. These vary from benign processes such as reactive lymph nodes, pleomorphic adenoma, and Warthin's tumor, to malignancies such as adenocarcinoma, adenoid cystic carcinoma, and mucoepidermoid carcinoma. Neoplasms of the parotid gland can pose a diagnostic challenge because conventional imaging features cannot differentiate benign from malignant lesions with complete certainty [1]. In conventional MRI examinations, most neoplasms of the parotid gland enhance with intravenous contrast. Therefore, the presence of enhancement, while essential to the identification and mapping of parotid neoplasms, does not differentiate between different

tumor subtypes. To further obfuscate clinical management, the most common benign tumor of the parotid gland (pleomorphic adenoma) can occasionally dedifferentiate into a malignant tumor [2]. Moreover, the accuracy of fine needle biopsy of parotid neoplasms can occasionally be limited due to sampling errors [3].

## GRASP

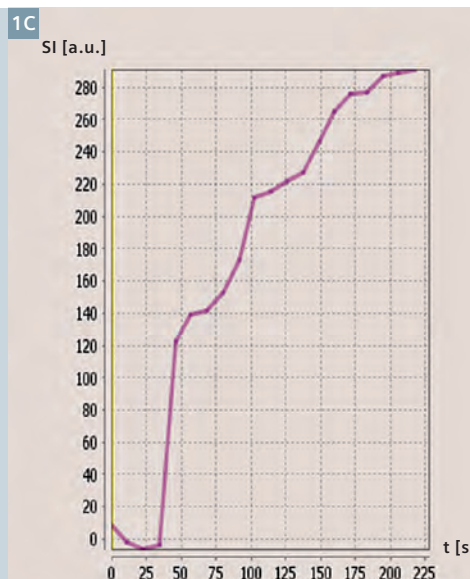
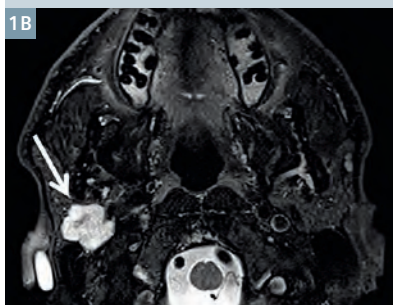
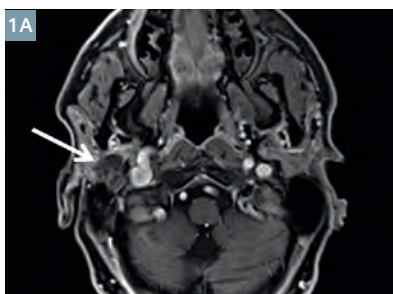
Golden-Angle Radial Sparse Parallel MR Imaging (GRASP<sup>1</sup>) is a novel imaging technique that combines golden-angle radial stack-of-stars sampling with a compressed sensing reconstruction [4], enabling motion-robust imaging at high spatial and temporal resolution. GRASP allows

a characterization of the dynamic contrast curve of parotid tumors. Numerous features of the contrast curve can be easily assessed, such as the wash-in and wash-out contrast slopes, the time-to-maximum-enhancement, area under the curve, and peak enhancement. Each of these features may differ amongst various parotid neoplasms, and provide an additional non-invasive method of interrogating parotid neoplasms. In addition, GRASP produces high-resolution, fat-suppressed images with excellent motion robustness allowing for precise localization and mapping of parotid neoplasms.

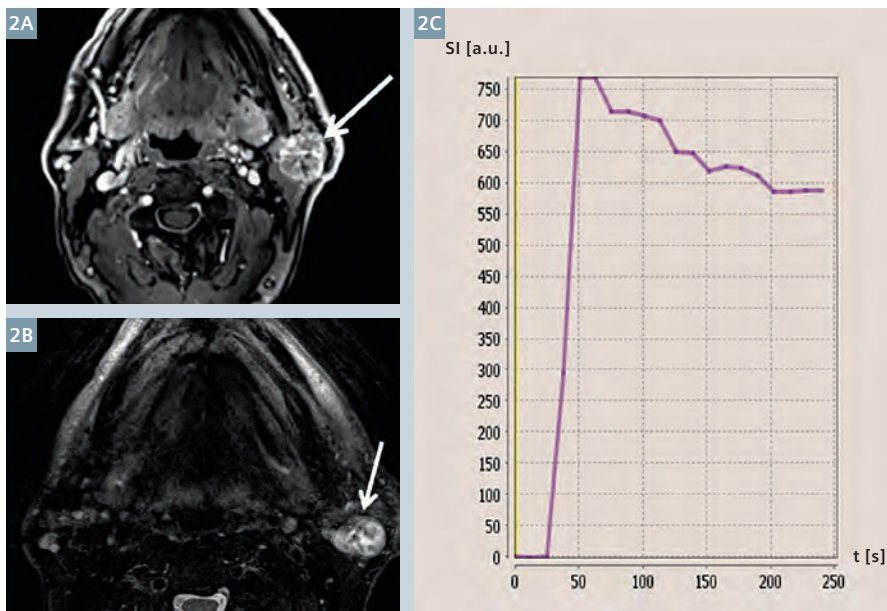
## Clinical cases

Two cases are included for illustration. Figure 1 shows GRASP imaging data of a parotid mass in a 67-year-old male.

<sup>1</sup> The product is still under development and not commercially available yet. Its future availability cannot be ensured.



**1** 67-year-old male patient with a right parotid pleomorphic adenoma. **(1A)** Composite GRASP image shows a lobulated mass in the right parotid gland demonstrating mild enhancement (arrow). **(1B)** T2-weighted imaging demonstrates hyperintense signal in the lesion (arrow). **(1C)** Dynamic contrast curve shows continuous gradual wash-in of contrast material during the image acquisition.



- 2 68-year-old male patient with a left parotid Warthin's tumor. (2A) Composite GRASP image shows a lobulated mass in the left parotid gland demonstrating moderate enhancement (arrow). (2B) T2-weighted imaging demonstrates predominantly hyperintense signal in the lesion (arrow). (2C) Dynamic contrast curve shows steep wash-in slope, sharp early peak of contrast enhancement, and more gradual wash-out of contrast material.

Figure 1A is a high-resolution post-contrast image demonstrating that the mass has mild heterogeneous enhancement, and contains lobulated margins. Figure 1B shows that the lesion is hyperintense on T2-weighted imaging. Figure 1C demonstrates the dynamic contrast curve after processing of the GRASP data. The contrast curve demonstrates a gradual and continuously rising wash-in of contrast material. The imaging appearance and contrast curve characteristics were consistent with a pleomorphic adenoma [5], and this proved to be the case on pathologic analysis.

Figure 2 shows GRASP imaging data of a left parotid mass in a 68-year-old male. Figure 2A shows that the mass demonstrates moderately avid heterogeneous enhancement, and contains lobulated margins. Figure 2B shows that the lesion is predominantly hyperintense on T2-weighted imaging. Figure 2C demonstrates the dynamic contrast curve, which is strikingly different than the case shown in Figure 1. In this case, the contrast curve shows a sharp wash-in, an early peak, and relatively early wash-out of contrast material. Though the conventional imaging characteristics in this case were non-specific, the contrast curve was characteristic of a Warthin's tumor [5], which proved to be the case upon pathologic analysis.

## Conclusion

Improving the diagnostic specificity in assessing parotid neoplasms is only one among many potential applications for GRASP in the head and neck. Examples include assessment of lymph node status in cancer patients, differentiation of tumor recurrence from inflammation in treated patients, or differentiation of tumor types in other organs of the head and neck. At our institution, GRASP is performed in all of our clinical head and neck MRI scans, and it routinely impacts on our diagnostic performance.

## References

- Christe A, Waldherr C, Hallett R, Zbaeren P, Thoeny H. MR imaging of parotid tumors: typical lesion characteristics in MR imaging improve discrimination between benign and malignant disease. *AJNR American journal of neuroradiology*. 2011;32(7):1202-7. doi:10.3174/ajnr.A2520.
- Antony J, Gopalan V, Smith RA, Lam AK. Carcinoma ex pleomorphic adenoma: a comprehensive review of clinical, pathological and molecular data. *Head and neck pathology*. 2012;6(1):1-9. doi:10.1007/s12105-011-0281-z.
- Daneshbod Y, Daneshbod K, Khademi B. Diagnostic difficulties in the interpretation of fine needle aspirate samples in salivary lesions: diagnostic pitfalls revisited. *Acta cytologica*. 2009;53(1):53-70.
- Feng L, Grimm R, Block KT, Chandarana H, Kim S, Xu J, Axel L, Sodickson DK,

Otazo R. Golden-angle radial sparse parallel MRI: combination of compressed sensing, parallel imaging, and golden-angle radial sampling for fast and flexible dynamic volumetric MRI. *Magn Reson Med*. 2014.

- Dong Y, Lei GW, Wang SW, Zheng SW, Ge Y, Wei FC. Diagnostic value of CT perfusion imaging for parotid neoplasms. *Dento maxillo facial radiology*.
- Chandarana H, Feng L, Block TK, Rosenkrantz AB, Lim RP, Babb JS, Sodickson DK, Otazo R. Free-breathing contrast-enhanced multiphase MRI of the liver using a combination of compressed sensing, parallel imaging, and golden-angle radial sampling. *Invest Radiol* 2013 Jan;48(1):10-6.
- Chandarana H, Block TK, Ream J, Mikheev A, Sigal SH, Otazo R, Rusinek H. Estimating liver perfusion from free-breathing continuously acquired dynamic gadolinium-ethoxybenzyl-diethylenetriamine pentaacetic acid-enhanced acquisition with compressed sensing reconstruction. *Invest Radiol*. 2015 Feb;50(2):88-94. 2014;43(1):20130237. doi:10.1259/dmfr.20130237.

## Contact

Sohil H. Patel, M.D.  
Department of Radiology  
New York University  
Langone Medical Center  
660 1<sup>st</sup> Ave  
New York, NY 10016  
USA  
sohil.patel@nyumc.org